

Split-Face Comparison of Photodynamic Therapy with 5-Aminolevulinic Acid and Intense Pulsed Light Versus Intense Pulsed Light Alone for Photodamage

MICHAEL H. GOLD, MD,*† VIRGINIA L. BRADSHAW, RN, NPC,*†
MOLLY M. BORING, RN, NPC,*† TANCY M. BRIDGES, RN, NPC,*† AND JULIE A. BIRON, BSc†

BACKGROUND Photodynamic therapy (PDT) with a 5-aminolevulinic acid (ALA) photosensitizing agent and a variety of lasers and light sources has been shown to enhance the treatment of photodamaged skin and its associated actinic keratoses (AKs). The efficacy of short-contact, full-face ALA by PDT in photorejuvenation has also been demonstrated.

OBJECTIVE To evaluate short-contact (30 to 60 min) ALA-PDT with intense pulsed light (IPL) activation by comparing ALA-PDT-IPL with IPL alone.

METHODS Sixteen patients were enrolled in a split-face study. One side of each patient's face received ALA-PDT-IPL and the other side received IPL alone. Three treatments were given at 1-month intervals, and follow-up visits occurred at 1 and 3 months after the final treatment.

RESULTS Thirteen patients completed the trial. Three months after the final treatment, improvement was greater in the ALA-PDT-IPL side than in IPL-alone side for all facets of photodamage—crow's feet appearance (55 vs 29.5%), tactile skin roughness (55 vs 29.5%), mottled hyperpigmentation (60.3 vs 37.2%), and telangiectasias (84.6 vs 53.8%). The clearance rate of AK lesions was also higher (78 vs 53.6%).

CONCLUSION Short-contact ALA-PDT-IPL brings about greater improvement in photodamaged skin and greater clearance of AK lesions than IPL alone, further confirming the usefulness of ALA-PDT in photorejuvenation.

Dr. Gold is a consultant for both Dusa Pharmaceuticals Inc. and Lumenis, Inc. He owns stock in both companies and performs research for both companies. The Levulan[®] Kerastick[®] was provided by Dusa. The intense pulsed light device used in this study was purchased at a discount from Lumenis.

Photodynamic therapy (PDT) with topically applied 5-aminolevulinic acid (ALA, 20%) continues to be one of the most exciting new developments in dermasurgery. Many dermatologic entities are being treated with ALA-PDT (Table 1), and new treatment paradigms are making this modality increasingly useful to dermasurgeons.

The concept of PDT is not new. Descriptions of PDT for the

treatment of skin cancers date back to the early 1900s.^{1,2} PDT requires a photosensitizer that can accumulate in dystrophic skin cells and sebaceous glands. The most common photosensitizing agent used in dermatology is ALA, first described by Kennedy and colleagues³ in 1990. This topically applied agent acts as a prodrug and can penetrate through the stratum corneum and into dystrophic skin cells and sebaceous gland, where it is

transformed into a highly photoactive porphyrin derivative, protoporphyrin IX (PpIX). PpIX can be activated by lasers and light sources as shown by its absorption curve.⁴ Activation produces a singlet oxygen species that selectively destroys cells.⁵

In 1999, Levulan[®] Kerastick[®] (5-aminolevulinic acid HCl, Dusa Pharmaceuticals Inc., Wilmington, MA) received US Food and Drug Administration (FDA)

*Gold Skin Care Center and †Tennessee Clinical Research Center, Nashville, Tennessee

TABLE 1. Dermatologic Entities Treated with 5-Aminolevulinic Acid Photodynamic Therapy*Dermatologic Entities*

Actinic keratoses
Photodamage and associated actinic keratoses*
Bowen's disease
Superficial basal cell carcinoma
Superficial squamous cell carcinoma
Cutaneous T-cell lymphoma
Kaposi's sarcoma
Malignant melanoma
Actinic cheilitis
Keratoacanthoma
Psoriasis vulgaris
Human papillomavirus
Molluscum contagiosum
Alopecia areata
Hirsutism
Acne vulgaris*
Sebaceous gland hyperplasia*
Hidradenitis suppuritiva*

*Common indications for 5-aminolevulinic acid photodynamic therapy in the United States in 2004. Adapted with permission from Gold and colleagues⁵

clearance for the treatment of nonhyperkeratotic actinic keratoses (AKs) of the face and scalp. The photosensitizing agent used most commonly in the United States, Levulan[®] Kerastick[®], comes as a plastic tube containing an applicator tip and two sealed glass ampoules. One ampoule contains ALA powder and the other contains an aqueous solution of ethanol (48% v/v) and other ingredients. Just before use, the ampoules (still in the plastic tube) are broken by manual pressure, and the contents are mixed by gentle rotation for several minutes.⁵

For the treatment of AKs, the original (Levulan[®] Kerastick[®]) protocol called for applying the ALA solution and allowing it to remain in contact with skin for 14 to 18 hours before exposing

the treated area to blue light for 16 minutes and 40 seconds (1,000 seconds). Phase II⁶ and phase III⁷ trials of this protocol showed statistically significant efficacy when AK lesions were treated individually. A second treatment was effective against lesions that had failed to respond initially, thus increasing overall efficacy. Phase II and phase III trials showed 85% and 88% clearance of AKs, respectively, when two treatments were given. Common adverse events in both the ALA-PDT and placebo groups were stinging or burning during therapy and, after therapy, itching, erythema, and edema. The treatment also resulted in the "PDT effect," a common name given to downtime with healing that lasted up to 1 week in some participants.

Of particular interest, though, was that more than 94% of trial participants noted an improvement in skin texture after treatment.

When the phase II and phase III trials were completed, investigators began to search for ways to make ALA-PDT more attractive to dermatologists. One possibility was to reduce the ALA contact time. To investigate this, Touma and colleagues,⁸ using ALA-PDT with blue-light activation, compared 1, 2, and 3 hour ALA incubation periods with the traditional 14 to 18 hours for 18 patients treated for facial AKs and photoaging. The results showed that ALA-PDT with 1, 2, or 3 hour ALA incubation was as efficacious as ALA-PDT with 14 to 18 hours of ALA incubation.

Using blue light activation and short-contact (up to 3 hours) ALA-PDT, Goldman and colleagues⁹ obtained 90% clearance of AKs, 72% improvement in skin texture, and 59% improvement in skin pigmentation. Of note, 62.5% of participants found this therapy to be less painful than cryotherapy.

Other investigators have evaluated ALA-PDT results with intense pulsed light (IPL) activation. Ruiz-Rodriguez and colleagues,¹⁰ using 4 hour ALA incubation, activated PpIX with IPL in 17 patients with AKs and photoaged skin. Two treatments removed 87% of AK lesions without

scarring or pigmentary changes. Gold¹¹ used short-contact (30 to 60 minute), full-face ALA-PDT with IPL activation to treat 10 patients with photodamaged skin. Three months after the last of the three treatments, improvements achieved were 90% in crow's feet, 100% in tactile skin roughness, 90% in mottled hyperpigmentation, and 70% in telangiectasias. In addition, 83% of targeted AKs had been cleared.

Avram and Goldman,¹² using 1 hour ALA incubation and IPL activation for 17 patients, reported 68% clearing of AKs as well as 55% improvement in telangiectasias, 48% improvement in pigmentary changes, and 25% improvement in skin texture after a single treatment.

Alexiades-Armenakas and colleagues¹³ used a 585 nm long-pulsed pulsed dye laser (PDL) with ALA-PDT to treat 41 patients with AKs. They reported excellent cosmetic results with both 3 hour ALA and 14 to 18 hour incubations.

These collective results suggest that short-contact ALA-PDT with activation by a variety of lasers and light sources improve photodamaged skin and clear AKs. Our purpose was to verify these results with a split-face investigator-sponsored clinical study using short-contact ALA-PDT with IPL activation on one side of the face and IPL alone on the other side. Several split-

face clinical trials utilizing ALA-PDT and a variety of light sources have recently been published.¹⁴⁻¹⁶

Methods

The clinical trial was performed at the Tennessee Clinical Research Center, Nashville, TN. The study was approved under the auspices of the Western Institutional Review Board (WIRB), Seattle, WA. All patients gave informed consent before participating. Patients were required to be over 18 years of age and have mild-to-moderate photodamage as judged by tactile skin roughness, crow's feet appearance, and the presence of mottled hyperpigmentation, facial telangiectasias, and at least three facial AKs. Points of references for the inclusion criteria are given in Table 2A-D. Exclusion criteria were previous treatment of the affected areas with ALA or blue light, IPL, or other forms of radiation. Patients were also excluded if they had received (1) topical retinoids or other skin care products containing hydroquinones, glycolic acids, or vitamin C and, for AKs, 5-fluorouracil or cryotherapy at least 4 weeks before the trial began and (2) systemic retinoids within 6 months before the trial began. Patients were allowed to use mild skin cleansers and encouraged to use sunscreens (SPF of 30 or higher) daily during the trial period.

Sixteen patients participated in the study. ALA (Levulan[®] Kera-

stick[™]), prepared as described previously,⁵ was applied to one-half of the face of each patient and allowed to incubate 30 to 60 minutes after the skin had been prepped with a vigorous acetone scrub, as is routine for ALA-PDT procedures. After ALA removal, the entire face was covered with a 2 to 3 mm layer of coupling gel, and then irradiated with the VascaLight[™] IPL device (Lumenis Inc., Yokneam, Israel). The IPL treatment parameters were 34 J/cm² fluence, double pulsing with a 20-m/s delay, 8 × 16 mm spot size, and 6 to 7 seconds between pulses. Cutoff filters—550 nm for Fitzpatrick skin types I to III and 570 nm for Fitzpatrick skin type IV—were used during irradiation. Following each procedure, the face was scrubbed with a mild cleanser to assure that any remaining ALA would be removed from the skin surface. Then, patients had a physical sunblock applied in the office setting and were instructed to wear a hat and to remain out of the sun for the next 24 to 36 hours, in an attempt to diminish the potential for adverse events and the potential for a PDT effect. Patients received three treatments spaced 1 month apart and made follow-up visits 1 and 3 months after the final treatment.

Patient responses were evaluated by physical examination and from photographs taken at each treatment session and follow-up visit. The photographs utilized were taken using a standard digital

TABLE 2A. AK Target Lesion Grading (Lesions Must be Grade 1 or 2 to Qualify)

At Visit 1, each lesion will be identified and graded; at subsequent visits, the lesions will be graded; a minimum of three lesions is required

- (0) Lesion cleared, no target lesion palpable or visible
- (1) Target lesion is slightly palpable, minimally keratotic AK, better felt than seen.
- (2) Moderately keratotic AK, easily seen and felt.
- (3) Very thick and/or markedly keratotic AK.

AK, actinic keratoses.

TABLE 2B. Tactile Roughness (Grade of 2 or More to Qualify)

Texture of the overall facial skin assessed by lightly palpating by stroking gently with the index finger

- (0) Skin is very smooth
- (1) Skin is smooth with very occasional rough area
- (2) Mild roughness
- (3) Moderate roughness
- (4) Severe roughness

TABLE 2C. Crow's Feet Evaluation (Grade of 2 or More to Qualify)

Fine Wrinkling Only in the Periocular area

- (0) None
- (1) Minimal
- (2) Mild
- (3) Moderate
- (4) Severe

TABLE 2D. Mottled Hyperpigmentation (Grade of 2 or More to Qualify)

For Uneven Pigmentation, include the Area Involved, the Color Intensity, and the Evenness of Pigment Distribution

- (0) Evenly pigmented skin
- (1) Light hyperpigmentation involving small areas
- (2) Moderate hyperpigmentation involving small areas; light hyperpigmentation involving moderate areas
- (3) Moderate hyperpigmentation involving moderate-sized areas; light hyperpigmentation involving large areas; small areas of heavy hyperpigmentation
- (4) Heavy hyperpigmentation

photograph system. Photographic analyses were performed by a blinded investigator during the evaluation process who was unaware as to which side was treated

with ALA-IPL or IPL alone. Tactile skin roughness, crow's feet appearance, mottled hyperpigmentation, facial telangiectasias, and facial AKs were graded (as

described in Table 2) and adverse events, if any, were recorded at each visit.

Results

Thirteen (seven men) of the 16 participants (81.25%) completed the study. Two of the three not completing the study withdrew early because they were unable to meet all the study requirements and the third was lost to follow-up. The median age of the 13 patients was 51.3 years (37-63). Results at the 3 month follow-up visits are presented in Table 3.

For all photoaging parameters, improvement was greater on the side of the face treated with ALA-PDT-IPL than on the side treated with IPL alone. The most common adverse effects, erythema and edema, were seen in fewer than 10% of the treatments and were noted on both sides of the face. Erythema and edema resolved without sequelae, and none of the patients had downtime as a result of the procedures. Clinical examples are shown in Figures 1 and 2.

Discussion

ALA-PDT is becoming the standard treatment for facial photodamage and AKs. The advent of short-contact, full-face ALA-PDT has greatly increased the popularity of this modality among dermatologists.

Our results confirm those of previous investigators, including

TABLE 3. Average Improvement (Response Rate for AKs) in Photoaging Parameters (n = 13)

Parameter	Improvement or Response Rate (%)	
	ALA-PDT/IPL	IPL
Crow's feet	55.0	29.5
Tactile skin roughness	55.0	29.5
Mottled hyperpigmentation	60.3	37.2
Telangiectasias	84.6	53.8
AKs	78.0	53.6

AK, actinic keratoses; ALA, 5-aminolevulinic acid (Levulan® Kerastick®); PDT, photodynamic therapy; IPL, intense pulsed light.

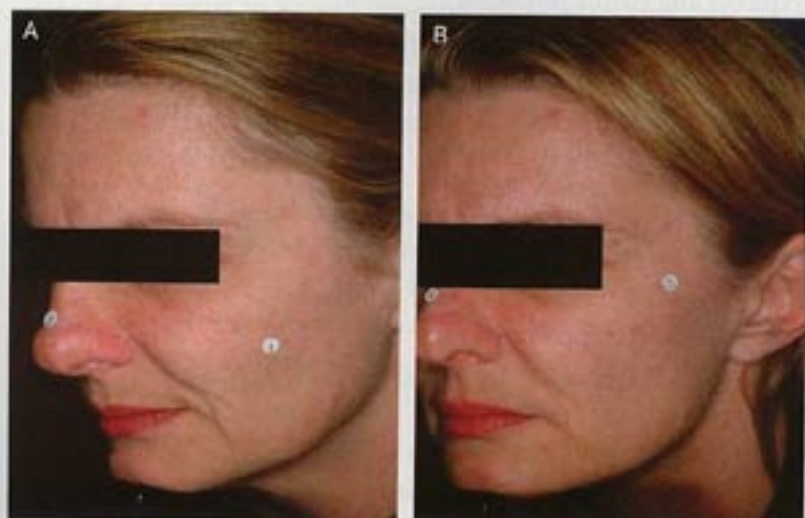

Figure 1. Left side of the face before ALA-PDT-IPL treatment (A) and 3 months after treatment (B). ALA, 5-aminolevulinic acid; PDT, photodynamic therapy; IPL = intense pulsed light.

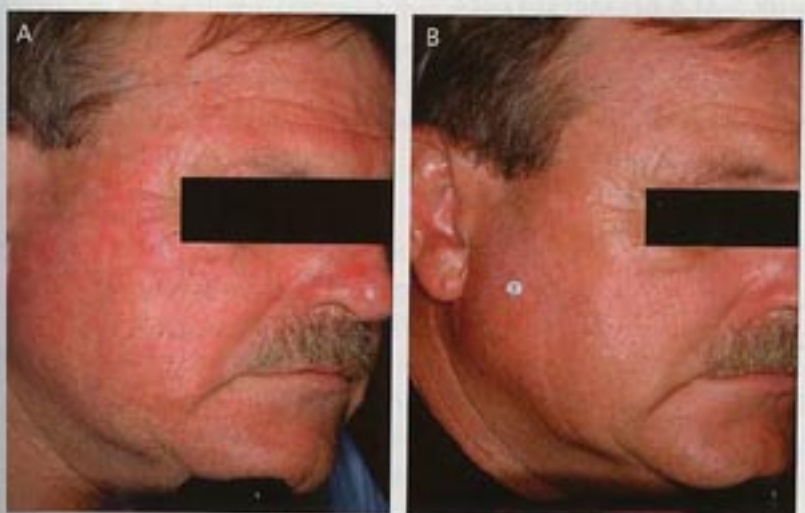


Figure 2. Right side of the face immediately after the first ALA-PDT-IPL treatment (A) and 3 months after treatment (B). ALA, 5-aminolevulinic acid; PDT, photodynamic therapy; IPL, intense pulsed light.

Bhatia and colleagues¹⁴ who conducted a split-face study similar to ours. In their trial, 20 subjects received PDT with IPL activation on the ALA side and IPL alone on the other side. Patients received three treatments at 3-week intervals, followed by two full-face treatments with IPL alone, also at 3-week intervals. Improvement was evaluated 4 weeks after the final treatment. In the ALA and non-ALA sides, respective improvements were 80% and 50% for photoaging overall, 95% and 65% improvement for mottled hyperpigmentation, and 55% and 20% in fine lines. Tactile skin roughness and sallowness did not change on either side of the face of any patient.

In addition, Alster and colleagues¹⁵ treated 10 patients with mild-to-moderate photodamage with ALA-IPL on one side of the face, with IPL only on the other side. Patients received two treatments at 4-week intervals and were followed for 6 months following the last IPL treatment. Results showed higher clinical improvement scores in all facets of photorejuvenation on the ALA-IPL treated side as compared with the IPL treated side of the face. Patients did have mild erythema and edema on the ALA-IPL side, compared with the IPL-treated side, but this resolved in all subjects without sequelae. Also, Key¹⁶ evaluated a split-face ALA trial utilizing a PDL. The results from this study also concluded that the ALA-PDL side did better than the side treated with the PDL alone.

Our study confirmed the results of previously reported clinical trials, which are important as we learn more and more about future applications for ALA-PDT. All facets of photodamage improved, including tactile skin roughness, facial telangiectasias, crow's feet, and the associated AKs. Tactile skin roughness was noted early on in studies of ALA-PDT where patients noted that their skin texture had improved; this was confirmed here. Facial telangiectasias also improved more with ALA than IPL alone. This has also been previously described but cannot be explained fully until more histologic examinations are performed. Improvements in crow's feet were also shown to be more pronounced on the ALA-IPL side than the IPL-treated side, similar to what was recently described by Goldberg and colleagues,¹⁷ in an investigation of the ultrastructural changes seen with ALA-IPL compared with IPL alone.

Of interest in our study and what continues to be a source of discussion involves what is considered an adverse event versus an expected outcome from this therapy. Our study showed that fewer than 10% of the participants experienced erythema and edema following their treatment, whether ALA-IPL or IPL alone. Part of the recent interest in short-contact, full-face therapy with ALA-IPL involves the amount of downtime and the reported PDT effect seen in most of the early clinical trials with ALA. We

strongly feel that this therapy should result in very little downtime and that there should be no PDT effect. Erythema and edema, while reported in some series, can be minimized by utilizing proper patient selection, well-defined parameters for patient preparation, and well-defined postoperative care, as was done in this clinical trial. The debate as to the need for erythema and edema following these therapies will continue for now; suffice it to say that we aim for the least amount in our patients treated with ALA, no matter which light source is utilized.

ALA-PDT with IPL or PDL activation appears to be useful for the treatment of facial photodamage and associated AKs. The split-face trial described here and the others described have confirmed the usefulness of this new therapeutic modality.

Short-contact, full-face therapy with 5-ALA has changed our outlook on how to treat photodamaged skin. We recommend three ALA-PDT-IPL treatments instead of the traditional five or six treatments with IPL alone. As always, maintenance therapies will be required along with proper skin care, including the use of sunscreens.

References

1. Von Tappeiner H, Jodlbauer A. Über Wirkung der photodynamischen (fluoreszierenden) Stoffe auf Protozoen und Enzyme. *Dtsch Arch Klin Med* 1904;80:427-87.
2. Jesionek A, Von Tappeiner H. Zur Behandlung der Hautcarcinome mit fluoreszierenden Stoffen. *Dtsch Arch Klin Med* 1905;85:223-7.
3. Kennedy JC, Pottier RH, Pross DC. Photodynamic therapy with endogenous protoporphyrin IX: basic principles and present clinical experience. *J Photochem Photobiol B* 1990;6:143-8.
4. Touma DJ, Gilchrist BA. Topical photodynamic therapy: a new tool in cosmetic dermatology. *Semin Cutan Med Surg* 2003;22:124-30.
5. Gold MH, Goldman MP. 5-aminolevulinic acid photodynamic therapy: where we have been and where we are going. *Dermatol Surg* 2004;30:1077-84.
6. Jeffes EW, McCullough JL, Weinstein GD, et al. Photodynamic therapy of actinic keratoses with topical aminolevulinic acid hydrochloride and fluorescent blue light. *J Am Acad Dermatol* 2001;45:96-104.
7. Jeffes E. Levulan[®]: the first approved topical photosensitizer for the treatment of actinic keratoses. *J Dermatol Treat* 2002;13:519-23.
8. Touma D, Yaar M, Whitehead S, et al. A trial of short incubation, broad-area photodynamic therapy for facial actinic keratoses and diffuse photodamage. *Arch Dermatol* 2004;140:33-40.
9. Goldman MP, Atkin D, Kincaid S. PDT ALA in the treatment of actinic keratoses: real world experience. *J Lasers Med Surg* 2002;14:Suppl:24.
10. Ruiz-Rodríguez R, Sanz-Sánchez T, Córdoba S. Photodynamic photorejuvenation. *Dermatol Surg* 2002;28:742-4.
11. Gold MH. Intense pulsed light therapy for photorejuvenation enhanced with 20% aminolevulinic acid photodynamic therapy. *J Lasers Med Surg* 2003;15:Suppl:47.
12. Avram D, Goldman MP. Effectiveness and safety of ALA-IPL in treating actinic keratoses and photodamage. *J Drugs Dermatol* 2004;3:S36-9.
13. Alexiades-Armenakas M, Geronemus R. Laser-mediated photodynamic therapy of actinic keratoses. *Arch Dermatol* 2003;139:1313-20.
14. Blacia AC, Dover JS, Stewart F, et al. Adjunctive use of topical aminolevulinic acid with intense pulsed light in the treatment of photoaging. (Presentation-controversies and conversations in cutaneous laser surgery, Mt. Tremblant, Canada, August 2004).

15. Alster TS, Tanzi EL, Welsh EC. Photorejuvenation of facial skin with 20% ALA and IPL treatment: a split face comparison. *J Drugs in Dermatol* 2005;4:35-8.
16. Key DJ. Aminolevulinic acid-pulsed dye laser photodynamic therapy for the treatment of photoaging. *Cosmetic Dermatol* 2005;18:31-6.
17. Goldberg DJ, Marmar ES, Phelps R. Ultrastructural changes seen after ALA-IPL photorejuvenation: a pilot study. *J Cosmet Laser Therapy* 2005;7:21-4.

Address correspondence and reprint requests to: Michael H. Gold, MD, Gold Skin Care Center, 2000 Richard Jones Road, Suite 220, Nashville, TN 37215, or email: goldskin@goldskin.com.

COMMENTARY

Remember the slogan, "Everything tastes better with Bluebonnet on it!" Like that ad campaign, this article suggests that every skin rejuvenation procedure goes better with "ALA on it." At first glance, this study appears to be well designed and makes a good case for adding aminolevulinic acid to IPL for photorejuvenation. The introduction of the paper woos the reader into a pro-ALA mood much like an anxious suitor on a first date. A cursory read will convince the reader that 20% ALA in short-contact mode exerts a "significantly" (although no statistical analysis is proffered) more robust response than IPL alone.

However, a more rigorous analysis leaves the audience pondering what really exerted the enhanced rejuvenative effects on the ALA-treated side. Certainly, based solely on the methods and results, a jury of competent dermatologists would have "reasonable doubt" regarding ALA's contribution to the observed rejuvenation. The photographs certainly do not make a compelling argument.

To their credit, the authors intend to present a fair and well-controlled study of ALA/IPL versus IPL alone. The split-face, prospective design is commendable. However, this paper shows only that if one rubs the skin very hard, and then places a 20% ALA solution on the skin for 30 to 60 minutes, photorejuvenation might be superior than if the physician just applied IPL alone. A truly controlled study would have been designed such that the only difference between the IPL and ALA-IPL side was the addition of ALA (the active ingredient). In other words, the "control" side should have been rubbed, after which the ALA vehicle alone should have been applied. Only in this manner, and with the assurance that the raters (both photographic and in person) were absolutely blinded as to which side was treated with the ALA and which was not, can the investigator reduce the number of confounding variables and bias, no matter how well the study was executed. So, no matter how noble the authors' intentions, this study cannot be accepted at face value to support the conclusion that an ALA effect alone is responsible for the enhanced effects on the "treated" side.

Still, the many papers extolling the benefits of short-contact pulsed light ALA PDT cannot be dismissed.¹⁻⁸ Even I have observed short-term reduction in the severity of AKs after pulsed-light short contact ALA-PDT, and there is undoubtedly some PDT effect with a short-contact pulsed light approach.⁹ However, much research and my own laboratory experiments suggest that there is very little protoporphyrin IX (PpIX) production even in lesional skin (AKs) after 30 to 60 minutes. Lesional skin will show more of a PDT effect because of an impaired stratum corneum that results in greater ALA penetration and therefore greater PpIX production.¹⁰ A recent study showed a ratio of 1.37 for PpIX concentration in AKs versus nonlesional skin after ALA application for 3 hours.¹¹

The authors of this present paper suggest that without so-called PDT effects, namely erythema, edema, and vesiculation, one can realize all the benefits of ALA. This is not consistent with